

The Society of Thoracic Surgeons Practice Guideline Series: Guidelines for the Management of Barrett's Esophagus With High-Grade Dysplasia

Hiran C. Fernando, MD, Sudish C. Murthy, MD, PhD, Wayne Hofstetter, MD, Joseph B. Shrager, MD, Charles Bridges, MD, ScD, John D. Mitchell, MD, Rodney J. Landreneau, MD, Ellen R. Clough, PhD, and Thomas J. Watson, MD

Boston University School of Medicine and Department of Cardiothoracic Surgery, Boston Medical Center, Boston, Massachusetts; Thoracic and Cardiovascular Surgery, Cleveland Clinic, Cleveland, Ohio; Stanford University School of Medicine, Stanford, California; Department of Thoracic and Cardiovascular Surgery University of Texas MD Anderson Cancer Center, Houston, Texas; Division of Cardiovascular Surgery, University of Pennsylvania Health System, Philadelphia, Pennsylvania; Division of Cardiothoracic Surgery, Department of Surgery, University of Colorado School of Medicine, Denver, Colorado; University of Pittsburgh Medical Center, Pittsburgh, Pennsylvania; The Society of Thoracic Surgeons, Chicago, Illinois; Division of Thoracic and Foregut Surgery, Department of Surgery, University of Rochester School of Medicine and Dentistry, Rochester, New York

The management of Barrett's esophagus with high-grade dysplasia is controversial. The standard of care has traditionally been esophagectomy. However, a number of treatment options aimed at esophageal preservation are increasingly being utilized by many centers. These esophageal-sparing approaches include endoscopic surveillance,

mucosal ablation, and endoscopic mucosal resection. In this guideline we review the best evidence supporting these commonly used strategies for high-grade dysplasia to better define management and guide future investigation.

(Ann Thorac Surg 2009;87:1993–2002)

© 2009 by The Society of Thoracic Surgeons

The management of Barrett's esophagus with high-grade dysplasia (HGD) is controversial. The standard of care has been esophagectomy. In the recently updated guidelines by the American College of Gastroenterology, however, the authors state that "esophagectomy is no longer the necessary treatment response to HGD" [1]. A number of treatment options aimed at esophageal preservation are increasingly being utilized by many centers. These esophageal-sparing approaches include endoscopic surveillance, mucosal ablation, and endoscopic mucosal resection (EMR). We believed that it was important to have a balanced guideline from our society addressing the role of esophageal resection, as well as these other approaches that are becoming increasingly adopted in clinical practice. The best evidence supporting the more commonly used strategies for HGD is reviewed. As will be seen in the following discussion, the evidence for most of these therapies is level B at best, despite the increasing popularity of these alternative approaches.

This paper was written by members of The Society of Thoracic Surgeons Treatment Options for High-Grade Dysplasia of the Esophagus Guideline Task Force whose names appear in the author line.

For the full text of The Society of Thoracic Surgeons (STS) Guideline on the Management of Barrett's Esophagus With High-Grade Dysplasia, as well as other titles in The STS Practice Guideline Series, visit <http://www.sts.org/sections/aboutthesociety/practiceguidelines> at the official STS website (www.sts.org).

Address correspondence to Dr Fernando, Department of Cardiothoracic Surgery, Boston Medical Center, 88 E Newton St, Robnson B402, Boston, MA 02118; e-mail: hiran.fernando@bmc.org.

Methods

Initially the Medline, Cochrane Library, and the Trip databases were searched for the terms Barrett's or high-grade dysplasia, or both, or surgery, photodynamic therapy and radiofrequency ablation, or a combination of these. The timeframe was not restricted. The Trip database returned two references. The Cochrane Library, which was restricted to randomized controlled trials, returned 91 of which 35 were initially considered relevant. The Medline PubMed returned 64 references of which four were review articles. The guideline was divided into four major components. These were (1) endoscopic surveillance, (2) mucosal ablation, (3) EMR, and (4) esophagectomy. The writing Task Force then met in person at The Society of Thoracic Surgeons and the American Association for Thoracic Surgery, and also by conference call on several occasions. After the Task Force reached consensus on the class and level of evidence for each of the recommendations (see [appendix](#)), the guidelines were posted on The Society for Thoracic Surgeons' (STS) website, which was opened to comments from the STS members. The guidelines then were submitted for approval by the Council on Quality, Research, and Patient Safety Operating Board and the STS Executive Committee prior to submission to *The Annals of Thoracic Surgery*.

Endoscopic Surveillance

Recommendations

Class I

- A rigorous biopsy protocol must be maintained throughout surveillance. (Level B Evidence)

- Histological evaluation of high-grade dysplasia should be undertaken by two pathologists experienced in interpreting esophageal metaplasia and dysplasia. (Level C Evidence)

Class IIa

- It is reasonable to limit endoscopic surveillance of high-grade dysplasia to high-volume centers with specific expertise in the management of Barrett's esophagus and preferably performed in the context of a clinical trial. (Level B Evidence)

Class IIb

- Surveillance may be considered for patients with flat, unifocal high-grade-dysplasia as they are at lower risk for progression to cancer compared to patients with multifocal HGD or those with dysplasia-associated lesions or masses. (Level B Evidence)

Patient Selection for Surveillance

Assumptions that must be made to justify surveillance are: (1) HGD is an entity distinct and distinguishable from intramucosal carcinoma, (2) HGD does not invariably progress to carcinoma, (3) if there is progression, it can be reliably detected at an early, curable stage, and (4) patients undergoing surveillance are reliable for follow-up and are candidates for further therapy if progression is diagnosed.

Progression of metaplasia through dysplasia to adenocarcinoma is a widely accepted theory of esophageal carcinogenesis [2, 3]. It is also known that most patients with Barrett's or low-grade dysplasia will not progress to invasive cancer. However, given the fact that HGD is frequently found in association with esophageal cancer, and unsuspected cancer has been found in 25% to 73% of esophagectomy specimens in which only HGD was preoperatively diagnosed, resection has been recommended for HGD in appropriate surgical candidates [4-9]. Retrospective analyses have led to the opinion that HGD is representative of potentially unstable epithelium in transition to cancer, and that its presence frequently indicates coexisting invasive carcinoma [10].

In contrast, it is becoming apparent that subgroups of HGD exist that may have a lower risk of cancer progression, and such patients have been placed under rigorous surveillance protocols [11-14]. The limited literature regarding surveillance of HGD is conflicting, consisting primarily of one prospective, nonrandomized study and three retrospective cohort studies [11-14]. The cohort studies were performed within the framework of prospective surveillance programs for Barrett's at experienced centers. All of the studies represent a cumulative total of 145 patients with mean follow-up ranging from 15 to 88 months. These studies agree that there are patients that may be at lower risk of progression that could potentially remain in surveillance. In fact, in one study, 46% of the patients undergoing surveillance for HGD regressed [15]. Other series have similarly reported regression of HGD during surveillance [13, 14].

There is also agreement that there are indicators that place a patient at higher risk for progression or for harboring synchronous invasive disease. Some centers have relied on pathologic indicators to separate higher risk from lower risk Barrett's. One group compared preoperative biopsy findings with those from esophagectomy specimens [16]. An experienced panel of pathologists reviewed all biopsies. Patients classified as HGD only had a 4.8% incidence of cancer. Patients classified as HGD suspicious for carcinoma had a 72% incidence of carcinoma in their esophagectomy specimens. Patients with multifocal HGD and HGD with dysplasia-associated lesions or masses are reported to have an estimated risk of concurrent invasive cancer in the range of 60% to 78% [11, 13]. It should be noted that patients with these features were excluded from some surveillance protocols [14]. Alternatively, patients without nodularity, so-called "flat" HGD, appear to be at lower risk for coincident cancer [12, 13]. Progression to cancer is also less likely in patients with unifocal (ie, limited or focal), flat, HGD [11, 14]. Weston and colleagues [14] reported on 15 such patients prospectively placed under intensified surveillance for unifocal HGD. Progression occurred in 8 of 15 patients with 4 of 8 progressing to invasive cancer, 2 of 8 to HGD with dysplasia-associated lesions or masses, and 2 of 8 to multifocal high-grade dysplasia. Among the four cancers definitively diagnosed, one was a T2M1 lesion. The others were intramucosal (n = 2) and submucosal (n = 1). Impressively, significant regression occurred in 7 of 15 (46%) patients who went from a diagnosis of unifocal HGD to Barrett's esophagus without dysplasia (4 patients) or low-grade dysplasia [16]. Of note, all 3 patients diagnosed with unifocal HGD within a short segment of Barrett's esophagus regressed during observation. It should be emphasized that a rigorous biopsy protocol was used (four quadrant biopsies every centimeter of Barrett's esophagus with jumbo forceps) throughout the study. Two experienced pathologists confirmed the histologic findings, and the mean follow-up was 37 months (range, 12 to 91). Although this group had some success with surveillance, 2 of the 4 patients diagnosed definitively as having cancer had progressed to cancer beyond the mucosa, leading the authors to conclude that an observational approach, even in unifocal HGD may not be justified.

There is some disagreement when comparing these findings with other reported series. Some authors report that patients with uncomplicated HGD progress to cancer at a much lower rate of 14% to 25% during follow-up [13, 15], and those cancers diagnosed during surveillance are generally superficial, particularly when rigorous biopsy techniques are used [17]. They conclude that progression to invasion is not absolute and that selected patients with HGD are able to retain their esophagus and will not show evidence of progression during follow-up. The incidence of cancers diagnosed at an advanced stage in each of the series previously described was approximately 2%.

Other anatomic variables believed to influence progression of HGD to invasive cancer, such as length of Barrett's segment and presence of a hiatal hernia have

been examined, but findings are contradictory [18, 19]. Although most would agree that following a patient with long-segment Barrett's esophagus is difficult, and these patients potentially carry a high risk for sampling error, some studies also indicate that short-segment Barrett's may be at similar cancer risk as longer segment disease [18].

Biopsy Protocol

There are no randomized trials comparing methods of biopsy. The Seattle Protocol (biopsies with jumbo forceps in four quadrants, along every centimeter of metaplastic epithelium with extra biopsies taken from suspicious areas) is advocated by some. Reid and colleagues [17] argued that cancer can be detected at an early stage of invasion and that rigorous biopsy protocols can distinguish patients with HGD from those with invasive disease. In their case-series, 48 cancers were detected in 45 patients of a total 123 patients with HGD under surveillance. This required a mean number of 163 biopsies from patients diagnosed with cancer (range, 44 to 571 patients) during a 2-month to 89-month period. Also demonstrated in this series were 2 of 45 patients (4.4%) diagnosed with submucosal cancer during surveillance, one with lymph node metastases.

All studies claiming success with surveillance for HGD have used rigorous biopsy protocols [11–14, 17]. A biopsy taken every 1 to 2 cm in four quadrants within the Barrett's segment is considered standard. Conversely, studies using less stringent surveillance, without rigorous biopsy protocols, report significant numbers of patients progressing to invasive and locally advanced cancers from HGD [9].

Not all authors agree that rigorous biopsy techniques are capable of detecting cancers developing during surveillance. In one study from a high-volume center, 28 patients were referred for resection with a diagnosis limited to HGD. Thirty-six percent of these patients (10 of 28) had invasive cancer in their surgical specimens, and 2 patients demonstrated submucosal invasion [5]. The authors concluded that unsuspected cancer was found frequently in surgical specimens despite a rigorous biopsy protocol using 4-quadrant jumbo biopsies every 2 cm along the length of the Barrett's. A decision to place a patient with HGD into surveillance must take into account the practicality of performing multiple, intense biopsy sessions at regular intervals. The frequency of endoscopy has most often been described at 3-month intervals, although the patients with stable dysplasia have been placed on 6-month intervals as well [13, 14, 17]. Even the most aggressive biopsy protocols may not be able to capture 100% of patients that progress from Barrett's esophagus to cancer. In addition, patients have been reported to progress from Barrett's metaplasia or low-grade dysplasia directly to cancer while under surveillance with an apparent rapid progression or "missed" HGD [2]. A better understanding of who is at risk of progression is critical to improving treatment strategies.

Advanced endoscopic imaging technologies, such as narrow-band imaging, auto-fluorescence, and confocal

laser endo-microscopy have been used in attempts to improve detection of dysplasia. Another approach is the use of vital stains, such as methylene blue, acetic acid, or indigo carmine, which can help direct and reduce the number of biopsies required to detect HGD with a segment of Barrett's [20]. These promising modalities have not currently demonstrated superiority to existing biopsy protocols.

Pathologist Interpretation of High-Grade Dysplasia

Histologic criteria for dysplasia were described in 1988 by Reid and colleagues [21]. Despite these criteria being accepted nearly 20 years ago, significant interobserver variability still exists among pathologists experienced in gastrointestinal dysplasia [22]. The key factor in determining whether a patient is a reasonable candidate for surveillance is the differentiation between HGD and intramucosal cancer, a task described by an expert in Barrett's dysplasia as "difficult at best" [10]. Ormsby and colleagues [22] found that among experienced gastrointestinal pathologists, interobserver agreement for distinguishing HGD from invasive cancer was only fair at $k = 0.56$. Furthermore, agreement did not substantially improve after establishment of uniform criteria [22]. Among the previously described surveillance studies, all but one [13] mandated that two experienced pathologists confirm the histology.

It is reasonable to question whether standard histologic examination is an adequate indicator of disease potential numerous publications describe alternative methods for predicting progression of Barrett's, including flow cytometry, loss of heterozygosity, immunohistochemistry (in particular for p53) and computerized morphometry, to name a few [23–28]. Although such methods have shown the ability to predict progression, none has done so with enough accuracy to replace the current standard of histology.

Mucosal Ablation of High-Grade Dysplasia

Recommendations

Class IIa

- Photodynamic therapy (PDT) should be considered for eradication of high-grade dysplasia (HGD) in patients at high risk for undergoing esophagectomy and for those refusing esophagectomy. (Level B Evidence)
- It is reasonable to use photodynamic therapy (PDT) to ablate residual intestinal metaplasia after endoscopic mucosal resection (EMR) of a small intramucosal carcinoma in high-risk patients. (Level B Evidence)

Class IIb

- Radiofrequency ablation (RFA) may be considered to treat patients with Barrett's metaplasia. (Level B Evidence)

- Radiofrequency ablation (RFA) may be effective for ablation of HGD; however further trials are needed before this can be recommended in preference to currently available ablative therapies. (Level B Evidence)

Several methods of mucosal ablation have been reported for HGD. Of these, PDT is the most widely used. Recently RFA has been introduced into practice and is being studied in many of the same centers that have advocated PDT. This section reviews the current data for PDT and RFA.

Photodynamic Therapy for High-Grade Dysplasia

Photodynamic therapy involves the systemic administration of a photosensitizer (usually a porphyrin derivative or precursor) that selectively accumulates in neoplastic esophageal mucosal cells. Endoscopic delivery of low-energy, non-thermal laser light at a specific wavelength activates the chemical, leading to singlet oxygen formation and the destruction of these cells. Photodynamic therapy balances depth and completeness of mucosal ablation against the development of complications, most notably esophageal strictures or perforations.

Several trials have assessed the effectiveness of PDT alone for HGD. Most such trials involve relatively small patient numbers with only short-term to medium-term follow-up [29-34]. Trials demonstrating the effectiveness of PDT at reducing the development of cancer beyond 5 years are lacking. A consistent finding among several studies has been the occurrence of persistent visible or buried metaplastic mucosa at risk for subsequent malignant transformation. As the depth of injury with PDT is generally limited to the mucosa or submucosa, occult invasive cancers that penetrate more deeply are also inadequately ablated.

A single multicenter, prospective, randomized, controlled trial comparing PDT plus omeprazole versus omeprazole alone for treatment of Barrett's esophagus with HGD was published in 2005 [35]. Two-hundred eight patients were enrolled from 30 international centers; 138 patients received PDT with omeprazole (20 mg twice a day), and 70 received omeprazole (20 mg twice a day) alone (2:1 randomization). Surveillance endoscopies were performed every 3 months, until four consecutive quarterly biopsies were negative for HGD, and then every 6 months thereafter. Mean follow-up was 24.2 months in the PDT plus omeprazole group and 18.6 months in the omeprazole cohort. The HGD was eliminated in 77% of the patients receiving PDT, plus omeprazole and in 39% receiving omeprazole alone ($p < 0.0001$). Invasive cancer developed in 13% of the PDT patients compared with 28% treated with omeprazole alone ($p = 0.006$). The most common PDT-associated adverse events included mild photosensitivity reactions (69%), esophageal strictures (36%), vomiting (32%), and chest pain (20%). No procedure-related mortality occurred. Recently, 5-year follow-up data from this study were published [36]. At 5 years, cancer had developed in 15% of

the PDT patients compared with 29% ($p = 0.027$) of the omeprazole group. However, it should be noted that follow-up was available in only 61 of 208 patients.

Although the available data confirm the feasibility of PDT for ablation of HGD, several concerns exist. In the absence of microscopic assessment of esophagectomy specimens, the true incidence of complete elimination of HGD and cancer can not be assessed. The development of cancer in 15% of patients treated with PDT argues against the use of this modality in patients otherwise eligible for esophagectomy. In addition, the inability to monitor buried metaplastic mucosa after therapy risks occult progression of invasive cancer, potentially to an incurable stage [37].

A retrospective comparison of 129 PDT patients and 70 esophagectomy patients treated for a preoperative diagnosis of HGD was recently published [38]. Median follow-up was 59 months for the PDT group and 61 months for the esophagectomy group. In the PDT group, persistent HGD was noted in 33 patients (25.6%) at 1 year and strictures requiring dilation occurred in 27%. Cancers developed in 8 patients (6.2%) during follow-up (five intramucosal and three submucosal cancers), 7 subsequently underwent esophagectomy. None of the 7 patients had nodal metastases.

In the esophagectomy group, 9 patients (12.8%) had carcinoma in the resected specimens. Four had intramucosal tumors, five had submucosal tumors, and none had nodal metastases. There was 1 postoperative death (1.4%) and esophageal strictures developed in 9 patients (12.6%). The most striking finding in this study was that the overall survival was similar between the groups. Cancer-free survival was also similar, although there was a trend ($p = 0.06$) toward a lower survival in the PDT group.

This nonrandomized study has led some gastroenterologists to conclude that ablation and esophagectomy are in fact equivalent therapies for HGD. These results should be interpreted with caution. The groups were not matched. The PDT patients were older with more cardiac disease and lower performance status. In a younger and healthier group of patients, a higher proportion of deaths related to cancer is more likely. The mean length of Barrett's was less in the PDT group. Finally, it is interesting to note that the incidence of occult cancers found at surgery was less in this series compared with that typically reported, including an earlier study from the same center [39]. It was postulated that the reasons for the lower rates of occult cancer were related to better surveillance endoscopy and the more frequent use of EMR in this series.

Radiofrequency Ablation for HGD

Radiofrequency ablation using the HALO³⁶⁰ System (BarrX Medical Inc, Sunnyvale, CA) has been recently introduced into clinical practice. This uses a balloon-based array to deliver a high-power, ultra-short burst of ablative energy to the abnormal esophageal epithelium. This system appears to be safe and effective for Barrett's,

and clinical trials are currently underway for HGD. No phase III data are currently available, and most data are currently in abstract form.

A two-phase prospective, multicenter study of RFA has recently been published [40]. In the first phase, dosimetry was evaluated in 32 patients with Barrett's esophagus, delivering from 6 to 12 J/cm². In the second phase, effectiveness was evaluated in 70 patients. A dose of 10 J/cm² was performed using two treatment sessions. Surveillance biopsies were performed every 2 cm at 1, 3, 6, and 12 months, with a second ablation performed if Barrett's was still present at 1 or 3 months. A complete response was seen in 70% of patients with no strictures or buried glands seen in greater than 4,306 biopsies. The low stricture rate is encouraging when compared with that seen after PDT. In another small multi-center trial, 13 patients underwent ablation of nontumor bearing esophagus with either 8, 10, or 12 J/cm² immediately prior to an esophagectomy [41]. Complete epithelial removal without injury to the submucosa or muscularis propria occurred in all patients treated with a dose of 10 or 12 J/cm². It seems that the ablation with RFA is truly limited to the epithelium with appropriate dosimetry and probably accounts for the low stricture rate compared with PDT.

In a similar study design, 8 patients underwent ablation of 1 or 2 circumferential segments of HGD immediately prior to an esophagectomy [42]. A total of 10 segments were ablated using 10, 12, or 14 J/cm². Ablation depth increased with higher energy density and number of applications. Mild edema in the submucosa was seen with 14 J/cm² ablations. Ablation reached the muscularis mucosa when four ablation applications were used. Currently 12 J/cm with two ablation applications is recommended for dysplastic esophageal epithelium. No evidence of HGD was seen in 9 of 10 specimens (90%).

A phase I study from Europe evaluated 11 patients with low-grade dysplasia (n = 2) and HGD (n = 9) [43]. The median length of Barrett's was 5 cm. Complete remission of dysplasia and Barrett's was seen in all 11 patients (100%) at a median follow-up of 14 months. A multi-center prospective registry involving 142 patients with HGD was recently reported [44]. Surveillance was performed every 3 months with a median follow-up of 12 months in 92 patients. No evidence of HGD or cancer was seen in 90.2% of patients. Two patients (1.4%) underwent subsequent esophagectomy and both demonstrated intramucosal cancer on surgical pathology. The preliminary results of a randomized sham-controlled trial were recently presented [45]. This study involved a 2:1 randomization of 127 patients to RFA or sham. The primary end points were complete eradication of dysplasia and intestinal metaplasia at 12 months. Among 58 patients with 12-month data, there was a 67% clearance of HGD with RFA compared with 0% for the sham group. Although these represent interim results and are not yet in full publication, this study has supported the increasing preference for RFA over PDT in many centers. It is possible that as more mature data becomes available that RFA may replace PDT for mucosal ablation of HGD.

Endoscopic Mucosal Resection for High-Grade Dysplasia

Recommendation

Class IIa

- It is reasonable to use endoscopic mucosal resection (EMR) to excise discrete esophageal mucosal nodules that are small, flat, or polypoid in nature, and not invading deeper than the submucosa. Due to the frequent multi-focality of Barrett's, a concomitant mucosal ablative procedure is frequently required to assure complete eradication of disease. (Level B Evidence)

Endoscopic mucosal resection has been used to excise discrete mucosal nodules in the setting of Barrett's esophagus with HGD or intramucosal carcinoma, as well as to remove entire segments of metaplastic mucosa. The EMR was first described in Japan for excision of flat or polypoid esophageal mucosal tumors, particularly squamous cell carcinoma [46, 47]. For excision of discrete mucosal nodules, endoscopic ultrasonography is generally performed prior to EMR to exclude invasion of the tumor into the muscularis propria or deeper, which is a contraindication to the use of this technique. For tumors that seem to be invading the submucosa on endoscopic ultrasonography, EMR should be performed to confirm the depth of invasion, given the inaccuracy of endoscopic ultrasonography in determining submucosal involvement. A major advantage of EMR compared with mucosal ablative procedures is the availability of a large biopsy specimen for histologic assessment, including margins that are both lateral and deep. An EMR without a subsequent esophagectomy is appropriate only for neoplasms limited to the mucosa, in which the incidence of lymph node metastasis has been shown not to exceed approximately 5% [48]. Once tumors penetrate the muscularis mucosa to involve the submucosa, the incidence of nodal metastasis exceeds 20%. Esophagectomy with lymphadenectomy should ideally be performed in such patients. However even this approach is being challenged in some centers. A recent report documented EMR with or without additive mucosal ablation for 21 patients with submucosal tumors involving only the upper third of the submucosa [49]. Complete remission was achieved in 18 of 19 patients who were considered to have completed all planned endoscopic procedures. At a mean follow-up of 62 months, 5 of 18 patients (28%) demonstrated recurrent tumors.

The specimens obtained from EMR provide a more accurate assessment of depth of tumor penetration than afforded by endoscopic ultrasonography, which is often inaccurate at determining mucosal versus submucosal invasion. Such information may be used to tailor a subsequent esophagectomy. A vagal-sparing esophagectomy may be suitable for tumors limited to the lamina propria, in which the incidence of nodal metastasis is low, whereas a more aggressive approach, including a regional lymphadenectomy may be offered for tumors invading the submucosa or beyond [48].

Table 1. Esophagectomy for High-Grade Dysplasia

Study	No. of Patients	Complications/morbidity (%)	Mortality (%)	Occult Cancer
Williams and colleagues (75)	38	37	0	29
Fernando and colleagues (76)	28	54	4	39
Tseng and colleagues (64)	60	29	1.7	30
Sujendran and colleagues (77)	17	29	0	65
Reed and colleagues (61)	49	n/a	2	37
Rice (62)	111	n/a	0	45
	303		1	39.3*

* Weighted average.

A number of studies have assessed the use of EMR for treatment of Barrett's esophagus with HGD, either alone or in combination with other mucosal ablative techniques, such as PDT [15, 48, 50-52]. An EMR is used to excise discrete mucosal nodules, leaving the remainder of the metaplastic mucosa to be eliminated through an esophagectomy or mucosal ablation.

A single-center, prospective study from Germany evaluated EMR in 100 patients with adenocarcinoma of the esophagus considered at low-risk for lymphatic or systemic spread [50]. To qualify for inclusion in the study, the esophageal mucosal nodule had to be polypoid or flat (less than 20 mm in diameter), well or moderately-differentiated adenocarcinoma, limited to the mucosa based on endoscopic ultrasonography, biopsies, and radiography, and without evidence of invasion of lymphatic vessels or veins upon histologic assessment of the resected specimen. Forty-nine of the patients underwent concomitant mucosal ablation with argon plasma coagulation for short segment Barrett's, or PDT with 5-aminolevulinic acid for long-segment Barrett's. Complete local remission was achieved in 99 of 100 patients after a mean of 1.9 months and a maximum of three resections. Severe complications, such as esophageal perforation, major hemorrhage, strictures or death, were not observed. During follow-up averaging 36.7 months, recurrent or metachronous carcinomas were detected in 11% of patients. Repeat EMR was feasible in all cases. Calculated 5-year survival was 98%, with 2 deaths in the series related to other causes. More recently the same group reported on 349 who underwent a variety of endoscopic therapies, including 279 EMR [53]. There were 61 patients with HGD. At a mean follow-up of 63.6 months, complete response was seen in 96.6%. Surgical resection was only required in 3.7%, and 5-year survival was 84%.

Although promising, these results are from a single institution. The institutional expertise and infrastructure required for close follow-up will not likely be available in most centers. Another study has demonstrated that cap-assisted EMR frequently leaves HGD at the margins of resection [54]. In addition, several studies that have mapped the extent of dysplasia or occult carcinoma in esophagectomy specimens have confirmed the frequent multi-focality of disease, or an endoscopically visible lesion not correlated with the location of cancer [48, 55, 56]. Thus, the success of EMR depends on the ability of

adjunctive mucosal ablation to eliminate residual foci of metaplastic or neoplastic tissue, or with prompt endoscopic recognition of recurrent disease. Although preliminary results of circumferential EMR for resection of Barrett's esophagus associated with HGD or intramucosal carcinoma have been reported in a small number of patients with short-term follow-up, the published experience is far too limited at present to derive appropriate conclusions regarding efficacy, safety, and applicability of the technique [57].

Esophagectomy for High-Grade Dysplasia

Recommendations

Class IIa

- It is reasonable to use esophagectomy to eliminate high-grade dysplasia and any associated cancer. The majority of cancers found incidentally in patients with HGD are cured by esophagectomy. (Level B Evidence)
- Esophagectomy for Barrett's esophagus with HGD is reasonable and can be performed safely, with an operative mortality approaching 1%. (Level B Evidence)
- It is beneficial to perform esophagectomies for high-grade dysplasia in high-volume centers and by surgical teams with specific expertise in these procedures. (Level B Evidence)

Class IIb

- Vagal-sparing or minimally invasive esophagectomy may be considered for patients with high-grade dysplasia, because quality of life and the adjustment period may be improved by these approaches. (Level B Evidence)

Esophageal Cancer Prevention and Cure

Perhaps best considered in the context of prophylaxis of cancer, esophagectomy for HGD is effective and reasonable. The incidence of adenocarcinoma in all patients with Barrett's esophagus ranges from 0.2% to 2% per year, with a 0.5% annual incidence being the best supported [58, 59]. However, when HGD is present, 25% to 75% of patients will have concomitant unsuspected inva-

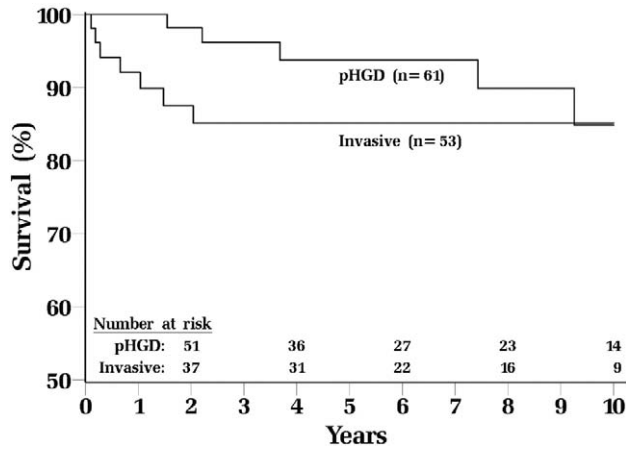


Fig 1. Overall survival of patients undergoing esophagectomy for preoperative diagnosis of high-grade dysplasia. Patient groups were stratified by presence of occult cancer in resection specimens. Invasive cancer rate for the entire cohort was 45%. (pHGD = pathological high-grade dysplasia.) (Adapted by permission from Macmillan Publishers Ltd: American Journal of Gastroenterology [62], © 2006.)

sive cancer (Table 1), with recent trends favoring incidences more towards the lower end of this range. Because molecular markers have as yet not been developed to identify occult esophageal cancer, the best cancer marker for adenocarcinoma remains HGD [60]. This has led to the belief that esophagectomy for HGD not only cures a significant proportion of patients with undiagnosed adenocarcinoma, but is also effective prophylaxis.

Multiple retrospective series support the notion that esophagectomy cures HGD and prevents cancer death [39, 61–64]. The 10-year survival, which may be more meaningful than 5-year survival (usually reported for cancer), from one surgical series is demonstrated in Fig 1 [61]. In this series, 45% (n = 53) of patients had incidental invasive cancer. T1a (intramucosal) tumors were found in 42, and T1b or higher were found in 11. The disease-specific 5-year survival for resected patients approaches 95% [61].

Morbidity and Mortality of Esophagectomy Specifically for HGD

A common argument against esophagectomy for HGD is that it is associated with excessive morbidity and mortality. However, historical claims of 50% morbidity and 10% mortality [65] are controverted by the results of many retrospective modern series particularly for HGD.

Most studies describe outcomes after esophagectomy principally for cancer, not HGD. This is an important distinction, because the majority of cancers tend to be more locally advanced and patients more debilitated preoperatively, particularly if undergoing neoadjuvant therapy. Comorbid diseases are generally less frequently encountered for patients with HGD. These factors, perhaps accompanied by stricter selection criteria imposed on patients with HGD, may explain the lower mortality of esophagectomy for HGD. The composite mortality from these studies is 1% (Table 1).

Additional factors that warrant consideration are the impact of hospital volume and surgeon experience. Hospitals in which a larger number of esophagectomies are performed demonstrate superior outcomes compared with lower volume hospitals [66, 67]. Moreover, increasing surgeon experience may similarly favorably impact operative mortality [68].

Morbidity after esophagectomy is not inconsequential. Postoperative arrhythmia, pneumonia, and anastomotic leak are the most prevalent early complications, although anastomotic stricture and reflux can be latent nuisances. The frequency of these morbidities seems to be less after esophagectomy for HGD or early invasive cancer, compared with esophagectomy for more advanced disease [69, 70].

Quality of Life After Esophagectomy

Longitudinal studies have demonstrated that the quality of life after esophagectomy is good to excellent. As expected, there is a prolonged adjustment period, and the quality of life of patients immediately after esophagectomy seems to be worse than comparable controls for the first 9 months after the operation [71]. In addition, patients learn to tolerate episodic reflux and intermittent diarrhea and dumping [39, 63]. Despite these concerns, by 5 years, esophagectomy patients equal or exceed quality-of-life scores in 7 of 8 domains compared with age and sex-matched population-based normal values, and almost 80% of patients report normal or near-normal eating habits [72]. Finally, long-term follow-up of patients undergoing esophagectomy for HGD demonstrates a reported quality of life similar to national norms, although 50% required anastomotic dilatation [39].

A number of centers are now using minimally invasive or vagal-sparing approaches to esophagectomy [73, 74]. Most data is single institutional and demonstrates the feasibility of these techniques. It is possible that these techniques decrease morbidity and result in a more rapid restoration of quality of life; however this will need to be determined in larger prospective studies.

Conclusion

The optimal management for HGD remains controversial. A number of factors must be considered when tailoring therapy, including patient comorbidities and desires, an assessment of the risk of the Barrett's segment containing or progressing to invasive cancer, as well as available institutional expertise and resources. If endoscopic surveillance is used, this should be in patients at lower risk for progression to cancer. It requires strict adherence to biopsy protocols, with experienced pathology interpretation available. This will be difficult in most clinical settings. Mucosal ablation is useful for the high-risk surgical patient and typically requires multiple endoscopic sessions for therapy and follow-up. An EMR can help evaluate and treat discrete mucosal nodules in the esophagus. The role of mucosal ablation or EMR, or both, for patients with HGD who are good candidates for esophagectomy is controversial and needs further inves-

tigation; if this approach is used, it should be limited to patients considered at low-risk for cancer progression. Esophagectomy performed in experienced centers remains the standard of care for patients deemed at good operative risk. Although the esophagectomy has been criticized as being overly aggressive in patients with a condition that may not be invasive, current data suggests that esophageal resection cures nearly all patients, many of whom will harbor an occult cancer. Due to many factors, including patient selection, outcomes after esophagectomy for HGD seem to be better than outcomes typically reported after esophagectomy for cancer.

Given the complexities in decision-making in regard to the management of HGD, the nuances in diagnosis and therapy, and the risks associated with either over-treatment or under-treatment, Barrett's esophagus with HGD is best managed in a center of excellence, preferably with input from experienced surgeons, gastroenterologists, and pathologists with focused interest in treating this disorder.

References

- Wang KK, Sampliner RE. Updated Guidelines 2008 for the diagnosis, surveillance and therapy of Barrett's esophagus. *Am J Gastroenterol* 2008;103:788-97.
- Hameeteman W, Tytgat GN, Houthoff HJ, van den Tweel JG. Barrett's esophagus: development of dysplasia and adenocarcinoma. *Gastroenterology* 1989;96:1249-56.
- Spechler SJ. The natural history of dysplasia and cancer in esophagitis and Barrett esophagus. *J Clin Gastroenterol* 2003;36:S2-5; discussion S26-8.
- Dar MS, Goldblum JR, Rice TW, Falk GW. Can extent of high grade dysplasia in Barrett's oesophagus predict the presence of adenocarcinoma at oesophagectomy? *Gut* 2003;52:486-9.
- Falk GW, Rice TW, Goldblum JR, Richter JE. Jumbo biopsy forceps protocol still misses unsuspected cancer in Barrett's esophagus with high-grade dysplasia. *Gastrointest Endosc* 1999;49:170-6.
- Korst RJ, Altorki NK. High grade dysplasia: surveillance, mucosal ablation, or resection? *World J Surg* 2003;27:1030-4.
- Nigro JJ, Hagen JA, DeMeester TR, DeMeester SR, Theisen J, Peters JH, Kiyabu M. Occult esophageal adenocarcinoma: extent of disease and implications for effective therapy. *Ann Surg* 1999;230:433-8; discussion 438-40.
- Tharavej C, Hagen JA, Peters JH, et al. Predictive factors of coexisting cancer in Barrett's high-grade dysplasia. *Surg Endosc* 2006;20:439-43.
- Thomas T, Richards CJ, de Caestecker JS, Robinson RJ. High-grade dysplasia in Barrett's oesophagus: natural history and review of clinical practice. *Aliment Pharmacol Ther* 2005;21:747-55.
- Montgomery E, Bronner MP, Goldblum JR, et al. Reproducibility of the diagnosis of dysplasia in Barrett esophagus: a reaffirmation. *Hum Pathol* 2001;32:368-78.
- Buttar NS, Wang KK, Sebo TJ, et al. Extent of high-grade dysplasia in Barrett's esophagus correlates with risk of adenocarcinoma. *Gastroenterology* 2001;120:1630-9.
- Levine DS, Haggitt RC, Blount PL, Rabinovitch PS, Rusch VW, Reid BJ. An endoscopic biopsy protocol can differentiate high-grade dysplasia from early adenocarcinoma in Barrett's esophagus. *Gastroenterology* 1993;105:40-50.
- Schnell TG, Sontag SJ, Chejfec G, et al. Long-term nonsurgical management of Barrett's esophagus with high-grade dysplasia. *Gastroenterology* 2001;120:1607-19.
- Weston AP, Sharma P, Topalovski M, Richards R, Cherian R, Dixon A. Long-term follow-up of Barrett's high-grade dysplasia. *Am J Gastroenterol* 2000;95:1888-93.
- Buttar NS, Wang KK, Lutzke LS, Krishnadath KK, Anderson MA. Combined endoscopic mucosal resection and photodynamic therapy for esophageal neoplasia within Barrett's esophagus. *Gastrointest Endosc* 2001;54:682-8.
- Zhu W, Appelman HD, Greenson JK, et al. Barrett's/cardiac high grade dysplasia is not a strong marker for concurrent carcinoma, unless architectural changes suspicious for adenocarcinoma are also present. the 95th Annual Meeting of the United States and Canadian Academy of Pathology, February 11-17, Atlanta, GA. *Mod Pathol* 2006;19(Suppl 1):126A.
- Reid BJ, Blount PL, Feng Z, Levine DS. Optimizing endoscopic biopsy detection of early cancers in Barrett's high-grade dysplasia. *Am J Gastroenterol* 2000;95:3089-96.
- Rudolph RE, Vaughan TL, Storer BE, et al. Effect of segment length on risk for neoplastic progression in patients with Barrett esophagus. *Ann Intern Med* 2000;132:612-20.
- Weston AP, Sharma P, Mathur S, et al. Risk stratification of Barrett's esophagus: updated prospective multivariate analysis. *Am J Gastroenterol* 2004;99:1657-66.
- Horwhat JD, Maydonovitch CL, Ramos F, et al. A randomized comparison of methylene blue-directed biopsy versus conventional four-quadrant biopsy for the detection of intestinal metaplasia and dysplasia in patients with long-segment Barrett's esophagus. *Am J Gastroenterol* 2008;103:546-54.
- Reid BJ, Haggitt RC, Rubin CE, Roth G, et al. Observer variation in the diagnosis of dysplasia in Barrett's esophagus. *Hum Pathol* 1988;19:166-78.
- Ormsby AH, Petras RE, Henricks WH, et al. Observer variation in the diagnosis of superficial oesophageal adenocarcinoma. *Gut* 2002;51:671-6.
- Reid BJ, Blount PL, Rubin CE, Levine DS, Haggitt RC, Rabinovitch PS. Flow-cytometric and histological progression to malignancy in Barrett's esophagus: prospective endoscopic surveillance of a cohort. *Gastroenterology* 1992;102:1212-9.
- Reid BJ, Levine DS, Longton G, Blount PL, Rabinovitch PS. Predictors of progression to cancer in Barrett's esophagus: baseline histology and flow cytometry identify low- and high-risk patient subsets. *Am J Gastroenterol* 2000;95:1669-76.
- Reid BJ, Prevo LJ, Galipeau PC, et al. Predictors of progression in Barrett's esophagus II: baseline 17p (p53) loss of heterozygosity identifies a patient subset at increased risk for neoplastic progression. *Am J Gastroenterol* 2001;96:2839-48.
- Sabo E, Beck AH, Montgomery EA, et al. Computerized morphometry as an aid in determining the grade of dysplasia and progression to adenocarcinoma in Barrett's esophagus. *Lab Invest* 2006;86:1261-71.
- Weston AP, Banerjee SK, Sharma P, Tran TM, Richards R, Cherian R. p53 protein overexpression in low grade dysplasia (LGD) in Barrett's esophagus: immunohistochemical marker predictive of progression. *Am J Gastroenterol* 2001;96:1355-62.
- Kerkhof M, Steyerberg EW, Kusters JG, et al. Aneuploidy and high expression of p53 and Ki67 is associated with neoplastic progression in Barrett esophagus. *Cancer Biomark* 2008;4:1-10.
- Overholt BF, Panjehpour M. Barrett's esophagus: photodynamic therapy for ablation of dysplasia, reduction of specialized mucosa, and treatment of superficial esophageal cancer. *Gastrointest Endosc* 1995;42:64-70.
- Overholt BF, Panjehpour M, Haydek JM. Photodynamic therapy for Barrett's esophagus: follow-up in 100 patients. *Gastrointest Endosc* 1999;49:1-7.
- Gossner L, Stolte M, Sroka R, et al. Photodynamic ablation of high-grade dysplasia and early cancer in Barrett's esophagus by means of 5-aminolevulinic acid. *Gastroenterology* 1998;114:448-55.
- Foroulis CN, Thorpe JA. Photodynamic therapy (PDT) in Barrett's esophagus with dysplasia or early cancer. *Eur J Cardiothorac Surg* 2006;29:30-4.

33. Pech O, Gossner L, May A, et al. Long-term results of photodynamic therapy with 5-aminolevulinic acid for superficial Barrett's cancer and high-grade intraepithelial neoplasia. *Gastrointest Endosc* 2005;62:24–30.
34. Laukka MA, Wang KK. Initial results using low-dose photodynamic therapy in the treatment of Barrett's esophagus. *Gastrointest Endosc* 1995;42:59–63.
35. Overholt BF, Lightdale CJ, Wang KK, et al., and the International Photodynamic Group for High Grade Dysplasia in Barrett's E. Photodynamic therapy with porfimer sodium for ablation of high-grade dysplasia in Barrett's esophagus: international, partially blinded, randomized phase III trial. *Gastrointest Endosc* 2005;62:488–98.
36. Overholt BF, Wang KK, Burdick JS, et al. Five-year efficacy and safety of photodynamic therapy with Photofrin in Barrett's high-grade dysplasia. *Gastrointest Endosc* 2007;66:460–8.
37. Mino-Kenudson M, Ban S, Ohana M, et al. Buried dysplasia and early adenocarcinoma arising in barrett esophagus after porfimer-photodynamic therapy. *Am J Surg Pathol* 2007;31:403–9.
38. Prasad GA, Wang KK, Buttar NS, et al. Long-term survival following endoscopic and surgical treatment of high-grade dysplasia in Barrett's esophagus. *Gastroenterology* 2007;132:1226–33.
39. Headrick JR, Nichols FC, 3rd, Miller DL, et al. High-grade esophageal dysplasia: long-term survival and quality of life after esophagectomy. *Ann Thorac Surg* 2002;73:1697–702.
40. Sharma VK, Wang KK, Overholt BF, et al. Balloon-based, circumferential, endoscopic radiofrequency ablation of Barrett's esophagus: 1-year follow-up of 100 patients. *Gastrointest Endosc* 2007;65:185–95.
41. Dunkin BJ, Martinez J, Bejarano PA, et al. Thin-layer ablation of human esophageal epithelium using a bipolar radiofrequency balloon device. *Surg Endosc* 2006;20:125–30.
42. Smith CD, Bejarano PA, Melvin WS, Patti MG, Muthusamy R, Dunkin BJ. Endoscopic ablation of intestinal metaplasia containing high-grade dysplasia in esophagectomy patients using a balloon-based ablation system. *Surg Endosc* 2007;21:560–9.
43. Gondrie JJ, Pouw RE, Sondermeijer CMT, et al. Stepwise circumferential and focal ablation of Barrett's esophagus with high-grade dysplasia: results of the first prospective series of 11 patients. *Endoscopy* 2008;40:359–69.
44. Ganz RA, Overholt BF, Sharma VK, et al. Circumferential ablation of Barrett's esophagus that contains high-grade dysplasia: a U.S. Multicenter Registry. *Gastrointest Endosc* 2008;68:35–40.
45. Shaheen NJ, Sharma P, Overholt BF, et al. A randomized, multicenter sham-controlled trial of radiofrequency ablation (RFA) for subjects with Barrett's esophagus containing dysplasia: interim results of the AIM dysplasia trial. In: *Digestive Diseases Week*. 2008. <http://myddw2008.bdmetrics.com/sessionsearch.aspx?pg=2&configid=1&day=7&keyword=shaheen>. Accessed May 2008.
46. Inoue H. Endoscopic mucosal resection for esophageal and gastric mucosal cancers. *Can J Gastroenterol* 1998;12:355–9.
47. Soetikno R, Kaltenbach T, Yeh R, Gotoda T. Endoscopic mucosal resection for early cancers of the upper gastrointestinal tract. *J Clin Oncol* 2005;23:4490–8.
48. Oh DS, Hagen JA, Chandrasoma PT, et al. Clinical biology and surgical therapy of intramucosal adenocarcinoma of the esophagus. *J Am Coll Surg* 2006;203:152–61.
49. Manner H, May A, Pech O, et al. Early Barrett's carcinoma with "low-risk" submucosal invasion: long-term results of endoscopic resection with a curative intent. *Am J Gastroenterol* 2008;103:2589–97.
50. Ell C, May A, Pech O, Gossner L, et al. Curative endoscopic resection of early esophageal adenocarcinomas (Barrett's cancer). *Gastrointest Endosc* 2007;65:3–10.
51. May A, Gossner L, Pech O, et al. Local endoscopic therapy for intraepithelial high-grade neoplasia and early adenocarcinoma in Barrett's oesophagus: acute-phase and intermediate results of a new treatment approach. *Eur J Gastroenterol Hepatol* 2002;14:1085–91.
52. Ell C, May A, Gossner L, et al. Endoscopic mucosal resection of early cancer and high-grade dysplasia in Barrett's esophagus. *Gastroenterology* 2000;118:670–7.
53. Pech O, Behrens A, May A, et al. Long-term results and risk factor analysis for recurrence after curative endoscopic therapy in 349 patients with high-grade intraepithelial neoplasia and mucosal adenocarcinoma in Barrett's oesophagus. *Gut* 2008;57:1200–6.
54. Abstracts of the 2004 American Society for Gastrointestinal Endoscopy (ASGE) Meeting, May 18–21. Orlando, FL. *Gastrointest Endosc* 2004;59:AB90–310.
55. Reid BJ, Weinstein WM, Lewin KJ, et al. Endoscopic biopsy can detect high-grade dysplasia or early adenocarcinoma in Barrett's esophagus without grossly recognizable neoplastic lesions. *Gastroenterology* 1988;94:81–90.
56. Cameron AJ, Carpenter HA. Barrett's esophagus, high-grade dysplasia, and early adenocarcinoma: a pathological study. *Am J Gastroenterol* 1997;92:586–91.
57. Seewald S, Akaraviputh T, Seitz U, et al. Circumferential EMR and complete removal of Barrett's epithelium: a new approach to management of Barrett's esophagus containing high-grade intraepithelial neoplasia and intramucosal carcinoma. *Gastrointest Endosc* 2003;57:854–9.
58. Egger K, Werner M, Meining A, et al. Biopsy surveillance is still necessary in patients with Barrett's oesophagus despite new endoscopic imaging techniques [comment]. *Gut* 2003;52:18–23.
59. Sharma P, Falk GW, Weston AP, Reker D, Johnston M, Sampliner RE. Dysplasia and cancer in a large multicenter cohort of patients with Barrett's esophagus. *Clin Gastroenterol Hepatol* 2006;4:566–72.
60. Montgomery E, Canto MI. Management of high-grade dysplasia in patients with Barrett's esophagus. *Clin Gastroenterol Hepatol* 2006;4:1434–9.
61. Reed MF, Tolis G Jr, Edil BH, et al. Surgical treatment of esophageal high-grade dysplasia. *Ann Thorac Surg* 2005;79:1110–5.
62. Rice TW. Pro: esophagectomy is the treatment of choice for high-grade dysplasia in Barrett's esophagus. *Am J Gastroenterol* 2006;101:2177–9.
63. Chang LC, Oelschlager BK, Quiroga E, et al. Long-term outcome of esophagectomy for high-grade dysplasia or cancer found during surveillance for Barrett's esophagus. *J Gastrointest Surg* 2006;10:341–6.
64. Tseng EE, Wu TT, Yeo CJ, Heitmiller RF. Barrett's esophagus with high grade dysplasia: surgical results and long-term outcome—an update. *J Gastrointest Surg* 2003;7:164–70.
65. Bailey SH, Bull DA, Harpole DH, et al. Outcomes after esophagectomy: a ten-year prospective cohort. *Ann Thorac Surg* 2003;75:217–22.
66. Swisher SG, Deford L, Merriman KW, et al. Effect of operative volume on morbidity, mortality, and hospital use after esophagectomy for cancer. *J Thorac Cardiovasc Surg* 2000;119:1126–32.
67. Kuo EY, Chang Y, Wright CD. Impact of hospital volume on clinical and economic outcomes for esophagectomy. *Ann Thorac Surg* 2001;72:1118–24.
68. Mathisen DJ, Grillo HC, Wilkins EW Jr, Moncure AC, Hilgenberg AD. Transthoracic esophagectomy: a safe approach to carcinoma of the esophagus. *Ann Thorac Surg* 1988;45:137–43.
69. Low DE, Kunz S, Schembre D, et al. Esophagectomy—it's not just about mortality anymore: standardized perioperative clinical pathways improve outcomes in patients with esophageal cancer. *J Gastrointest Surg* 2007;11:1395–1402.
70. Murthy SC, Law S, Whooley BP, Alexandrou A, Chu KM, Wong J. Atrial fibrillation after esophagectomy is a marker for postoperative morbidity and mortality. *J Thorac Cardiovasc Surg* 2003;126:1162–7.

71. Blazeby JM, Farndon JR, Donovan J, Alderson D. A prospective longitudinal study examining the quality of life of patients with esophageal carcinoma. *Cancer* 2000;88:1781-7.
72. Moraca RJ, Low DE. Outcomes and health-related quality of life after esophagectomy for high-grade dysplasia and intramucosal cancer. *Arch Surg* 2006;141:545-51.
73. Luketich JD, Alvelo-Rivera M, Buenaventura PO, et al. Minimally invasive esophagectomy: outcomes in 222 patients. *Ann Surg* 2003;238:486-94.
74. Peyre CG, DeMeester SR, Rizzetto C, et al. Vagal-sparing esophagectomy: the ideal operation for intramucosal adenocarcinoma and Barrett's with high-grade dysplasia. *Ann Surg* 2007;246:665-71.
75. Williams VA, Watson TJ, Herbella FA, et al. Esophagectomy for high grade dysplasia is safe, curative, and results in good alimentary outcome. *J Gastrointest Surg* 2007;11:1589-97.
76. Fernando HC, Luketich JD, Buenaventura PO, Perry Y, Christie NA. Outcomes of minimally invasive esophagectomy (MIE) for high-grade dysplasia of the esophagus. *Eur J Cardiothorac Surg* 2002;22:1-6.
77. Sujendran V, Sica G, Warren B, Maynard N. Oesophagectomy remains the gold standard for treatment of high-grade dysplasia in Barrett's oesophagus. *Eur J Cardiothorac Surg* 2005;28:763-6.

Appendix

Classification of Recommendation

Class I: Conditions for which there is evidence and/or general agreement that a given procedure is useful and effective.

Class II: Conditions for which there is conflicting evidence or a divergence, or both, of opinion about the usefulness and efficacy of a procedure.

Class II.a. Weight of evidence favors usefulness and efficacy.

Class II.b. Usefulness and efficacy is less well established by evidence.

Class III: Conditions for which there is evidence or general agreement, or both, that the procedure is not useful and effective.

Level of Evidence

Level A: Data derived from multiple randomized clinical trials.

Level B: Data derived from a single randomized trial or from nonrandomized trials.

Level C: Consensus expert opinion.